

# Clinical Case 1

---

P. Landreau. Orthopaedic Surgeon

E. Almusa. Radiologist

Aspetar. Orthopaedic and Sports Medicine Hospital

Doha

Qatar

# Case 1

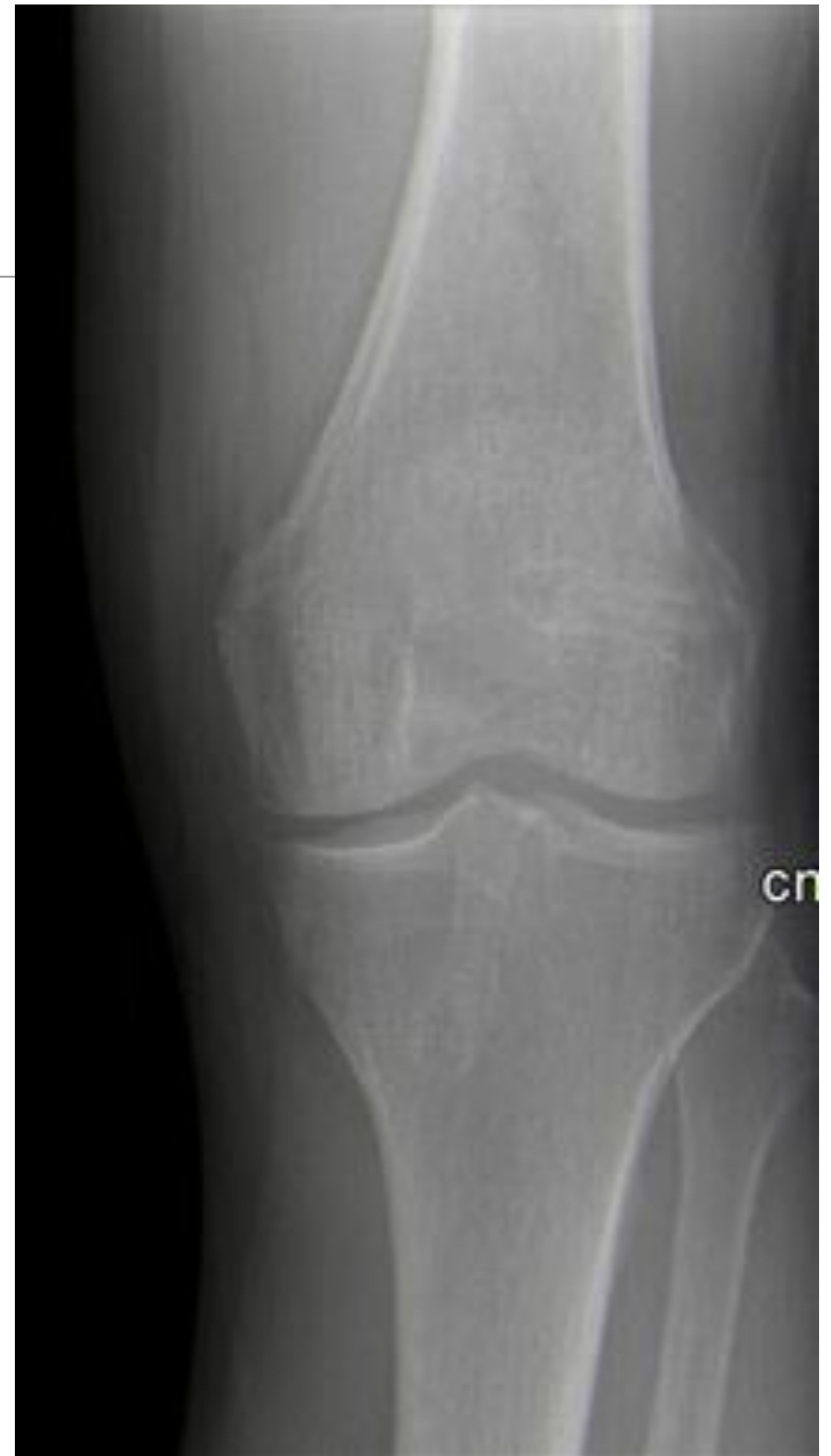---

- 50 y.o. Very active. Different sports.
- Left knee ACL reconstruction hamstrings 6 months.
- Still complaining lateral sharp pain, lateral to the patella, with “passage” syndrome. Between 40° and 90° of flexion. No instability.
- PE: Normal alignment. Full ROM. Mild swelling. Lachman and pivot negative. Lateral pain between 40° and 90° during squat. Local tenderness and small bump.

# Case 1

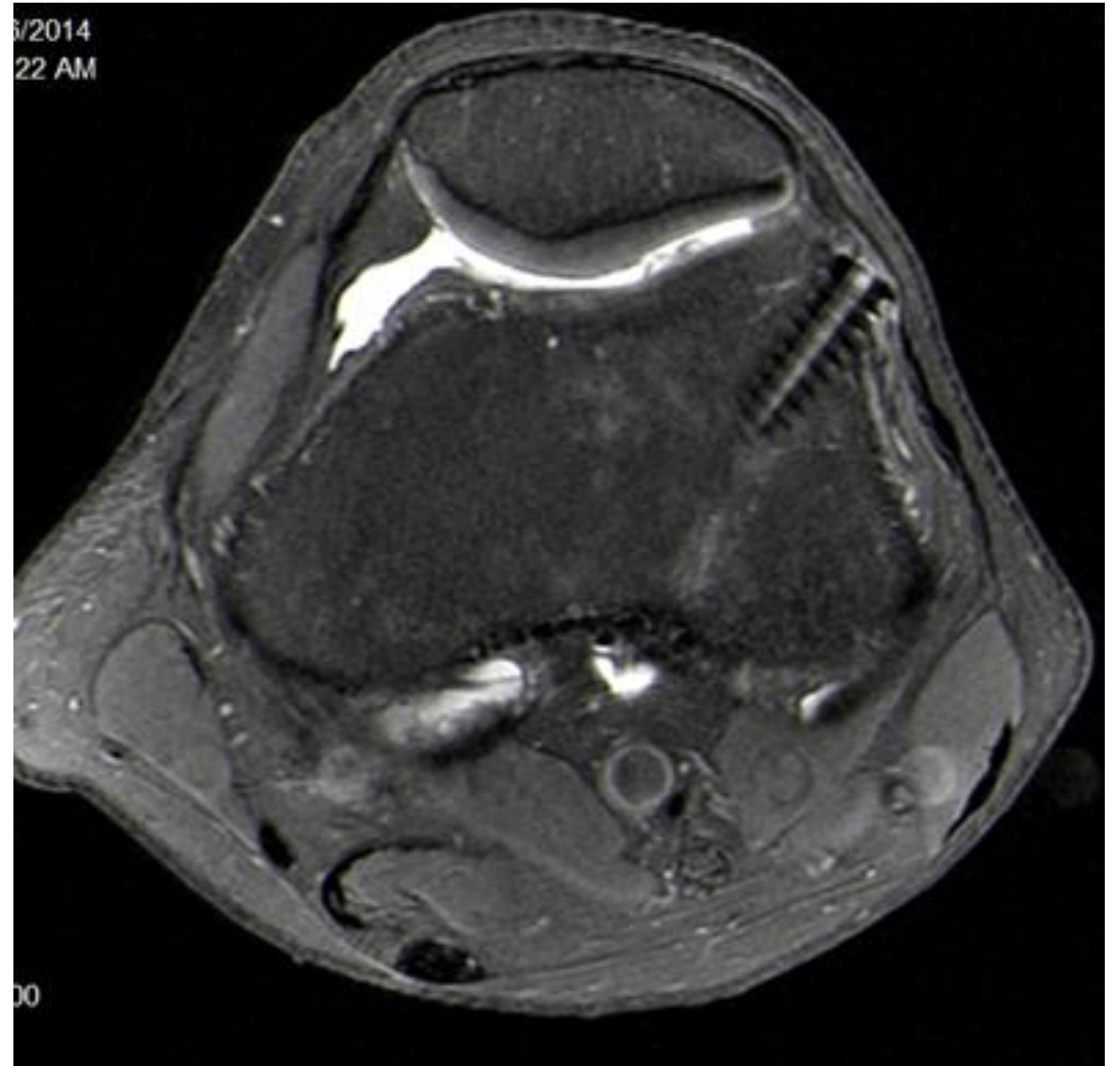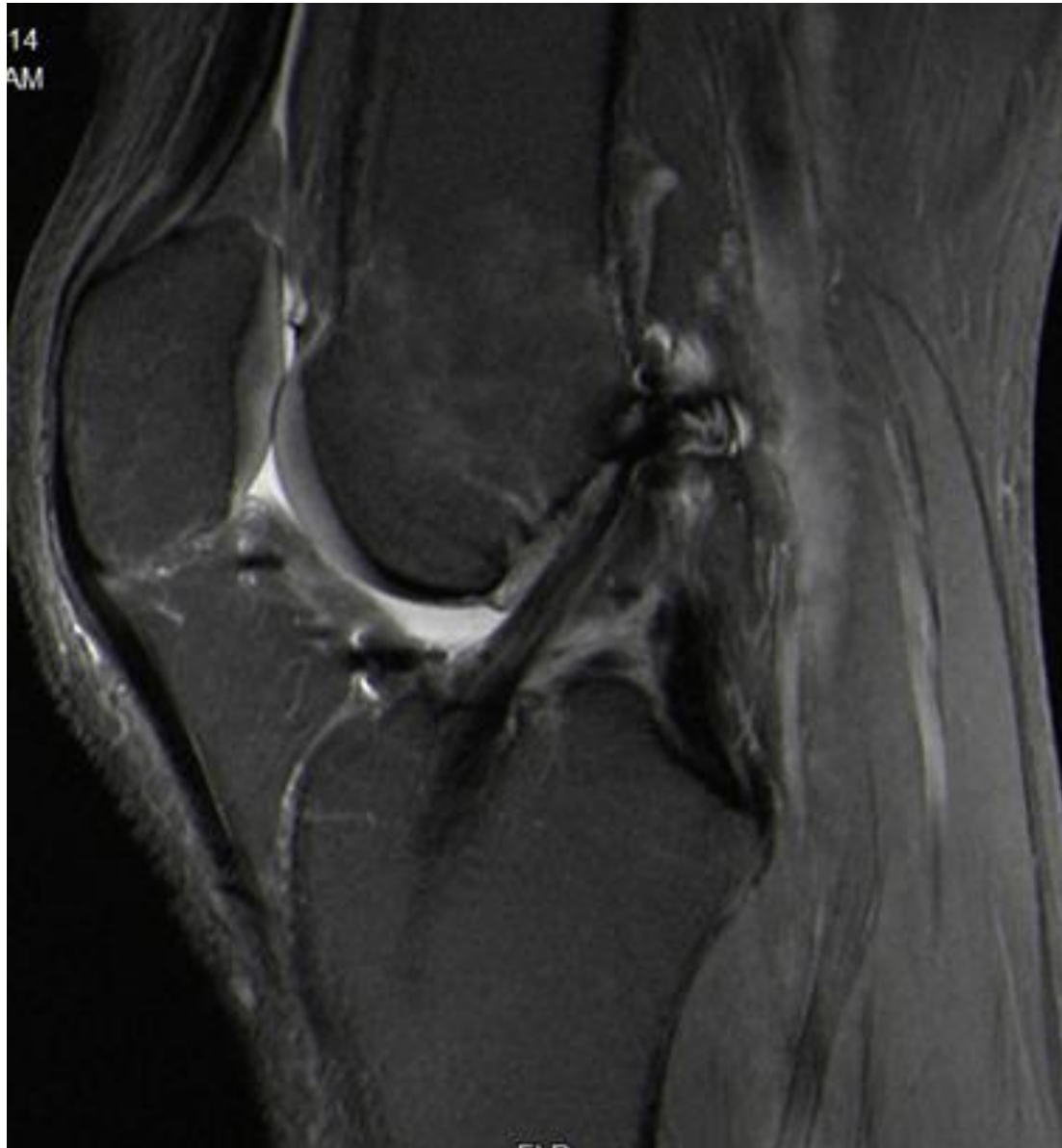---

Which additional imaging?  
What do you suspect?



# Case 1

---

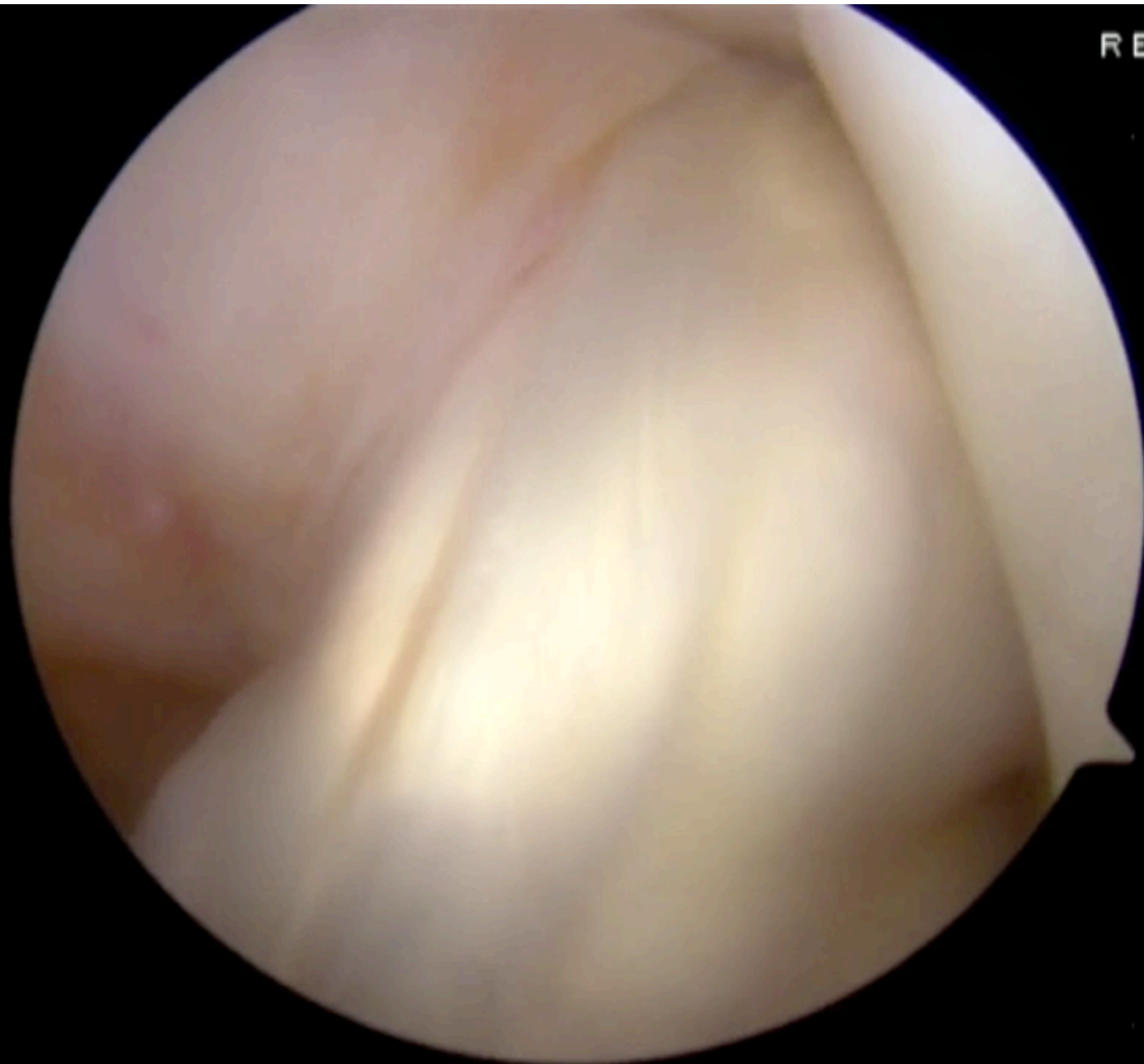


What is your plan?

# Case 1

6 \*

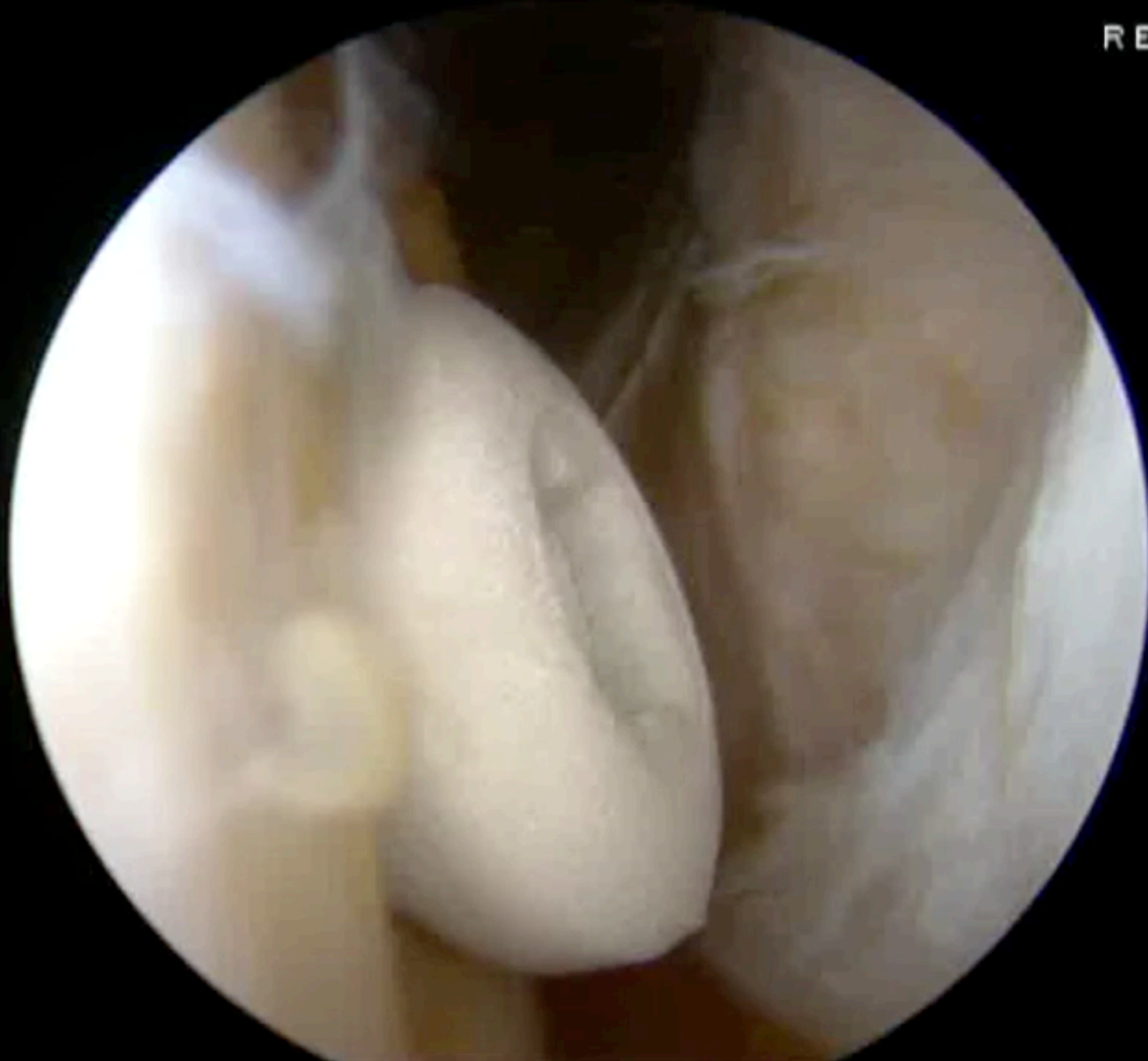REC \*



# Case 1

10\*

REC\*





# Case 1

12 \*

